

## Breathing Exercise and Early Mobilization in Patients Post Aortic Valve Replacement with Ascending Aortic Aneurysm

Hanabilla Rawdhatul Jannah<sup>1</sup>, Farid Rahman<sup>1</sup>, Purnomo Gani Setiawan<sup>2</sup>, Diani Qomaradewi Indah Sari<sup>2</sup>

<sup>1</sup>Faculty of Health Sciences, Universitas Muhammadiyah Surakarta, Surakarta, Jawa Tengah, Indonesia; <sup>2</sup>Department of Medical Rehabilitation, Dr. Kariadi General Hospital, Semarang, Indonesia

Correspondence: **Farid Rahman**: Jl. A. Yani, Mendungan, Pabelan, Kartasura, Sukoharjo, Jawa Tengah, Indonesia; fr280@ums.ac.id

### ABSTRACT

Postoperative respiratory distress and early decannulation are common complications following aortic valve replacement (AVR), particularly in patients with ascending aortic aneurysms. These conditions may delay recovery and increase the risk of adverse outcomes, highlighting the importance of early rehabilitation strategies. This case report aims to evaluate the effects of structured breathing exercises combined with progressive early mobilization during Phase I of cardiac rehabilitation in a postoperative AVR patient. A 61-year-old male patient admitted to the Cardiac Intensive Care Unit (CICU) underwent a structured intervention consisting of breathing exercises and progressive early mobilization. The program was conducted over three sessions, with monitoring of respiratory, hemodynamic, pain, and functional parameters. Following three intervention sessions, oxygen saturation improved from 94% to 100%, respiratory rate decreased from 27 to 20 breaths per minute, and pain intensity reduced from 4/10 to 0/10. Chest expansion increased by 0.5 cm at both axillary and xiphoid levels. Functional mobility, as measured by the ICU Mobility Scale, improved from 1 to 6. Hemodynamic parameters remained stable throughout the intervention, with no adverse cardiovascular events observed. In conclusion, structured breathing exercises combined with safe early mobilization appear to be effective in improving respiratory function, reducing pain, and accelerating functional recovery in high-risk patients following aortic valve replacement.

**Keywords:** cardiac rehabilitation; breathing exercises; early mobilization; aortic valve replacement; ascending aortic aneurysm

### INTRODUCTION

Heart valve disease is one of the leading causes of cardiovascular morbidity and mortality globally. According to data from the World Health Organization (WHO), more than 17 million people worldwide die from heart and blood vessel disease each year. The Indonesian Ministry of Health (2023) reports that cardiovascular disease causes 651,481 deaths per year, with 331,349 deaths due to stroke, 245,343 deaths due to coronary heart disease, 50,620 deaths due to hypertensive heart disease, and the rest due to other cardiovascular diseases [1,2].

Valve abnormalities can take the form of stenosis or regurgitation, both of which can interfere with intracardiac blood flow and reduce ventricular function. Aortic regurgitation (AR) occurs due to the inability of the aortic valve to close completely during diastole, causing blood to return to the left ventricle and creating excess volume and pressure. The left ventricle compensates for this condition through dilation and hypertrophy [3]. Primary causes of AR include bicuspid aortic valve, rheumatic heart disease, infective endocarditis, and calcific or myxomatous degeneration, while secondary causes are often associated with ascending aortic dilatation, aneurysm, genetic disorders, or aortic dissection. Previous studies have shown a higher risk of aortic complications in patients with bicuspid aortic valve accompanied by AR compared to stenosis or normal valve [4].

Ascending aortic aneurysm is one of the conditions that greatly contributes to cardiovascular morbidity and mortality due to its potential complications. Complications that may arise include aortic dissection, rupture, and sudden death. Clinically, this aneurysm is characterized by abnormal dilation of the ascending aorta segment, which is associated with the risk of these fatal events. The presence of aortic regurgitation (AR) can worsen the remodeling process of the ascending aorta wall, thereby increasing the likelihood of complications [5].

One treatment option for patients with heart valve abnormalities is cardiac surgery. This procedure aims to correct anatomical and functional abnormalities of the heart, particularly the valves. If valve repair is not possible, aortic valve replacement (AVR) is the most common procedure performed for aortic valve disease [6]. This case describes a patient who underwent not only aortic valve replacement (AVR) but also had ascending aortic aneurysm, a rarely reported combination that carries a higher risk of complications such as aortic dissection and rupture [4,5]. This report is intended for post-AVR patients with ascending aortic aneurysms treated at Dr. Kariadi General Hospital in Semarang. Physiotherapy interventions in the form of breathing exercises and early mobilization have been proven effective in post-cardiac surgery patients in general [7].

Breathing exercises play an important role in post-heart surgery respiratory recovery because they can increase lung ventilation, improve chest expansion, and prevent complications such as atelectasis and pneumonia [8]. In this case, the patient showed a decrease in oxygen saturation and an increase in respiratory rate above normal limits, requiring therapy to improve ventilation function [9,10]. Physiologically, breathing exercises can increase tissue oxygenation, reduce respiratory effort, and improve breathing efficiency, thereby supporting faster recovery [7].

Early mobilization in postoperative patients treated in the ICU, through active ROM in the upper and lower limbs, is an important intervention to prevent the risk of muscle weakness, improve physical function, and accelerate recovery. In this case, the patient exhibited overall physical weakness after undergoing surgery, making early mobilization a crucial part of therapy. Early mobilization has also been shown to support the extubation process in post-AVR patients and improve functional instability, thereby accelerating the rehabilitation process [11]. Therefore, the combination of breathing exercises and early mobilization is expected to increase respiratory capacity, improve activity tolerance, and prepare patients for the next phase of rehabilitation.

Phase I cardiac rehabilitation is the initial stage that begins while the patient is still hospitalized after heart surgery, with a focus on early mobilization and breathing exercises. This program aims to prevent deconditioning, reduce the risk of respiratory complications such as atelectasis, accelerate physical recovery, and support the patient's readiness for the next phase of rehabilitation [12]. Research shows that lung complications due to post-cardiac surgery deconditioning, such as atelectasis (30-72%), pleural effusion (24-63%), inflammatory lung injury (2-20%), long-term mechanical ventilation >48 hours (2-6%), and acute respiratory distress syndrome (ARDS) (0.4-2%) [13]. The importance of phase 1 rehabilitation is based on the condition of patients who experience instability in vital signs and overall physical weakness after surgery. Studies show that phase I rehabilitation is safe and beneficial for patients after valve surgery or aortic repair [14].

Although various studies have shown that breathing exercises and early mobilization are effective in improving respiratory function and functional capacity in post-cardiac surgery patients, most studies have been conducted on the general population without considering more

complex clinical conditions, such as the combination of aortic valve replacement [AVR] with ascending aortic aneurysm, which has a higher risk of complications. Furthermore, most studies have focused only on basic functional outcomes, while other important aspects such as respiratory function, complication prevention, and readiness for discharge in high-risk patients are still rarely considered [15,16]. To date, reports specifically discussing the effectiveness of combining breathing exercises and early mobilization in post-AVR patients with ascending aortic aneurysms are still very limited. Therefore, this case report was compiled to describe the role of breathing exercises and early mobilization in accelerating respiratory and mobility recovery in post-AVR patients with ascending aortic aneurysms at Dr. Kariadi General Hospital.

## METHODS

This study employed a case report design [17] to describe the physiological and functional responses to physiotherapy interventions, including breathing exercises and early mobilization, during Phase I cardiac rehabilitation in a patient following aortic valve replacement (AVR) with ascending aortic aneurysm. This study was conducted at Dr. Kariadi General Hospital in Semarang on patients treated in the Intensive Cardiac Care Unit (ICCU).

The patient is a 61-year-old man (initials: Mr. S), who works as a sand worker, with a medical history of hypertension and dyslipidemia. The patient was admitted to Dr. Kariadi General Hospital in Semarang with a definitive diagnosis of aortic valve replacement (AVR) accompanied by ascending aortic aneurysm. Physical therapy intervention began on the first three after surgery in the Cardiology Intensive Care Unit (ICCU).

On the first day after surgery, the patient complained of weakness, mild shortness of breath, and pain at the incision site. The patient had a history of shortness of breath during activities for 6 months, which worsened two months earlier with episodes of shortness of breath at night. The patient had no history of smoking or alcohol consumption, but had heavy physical activity at work without structured exercise. Family history indicated cardiovascular disease in a sibling.

On initial assessment, the patient was alert, cooperative, and hemodynamically stable, with oxygen support via nasal cannula (3 L/min). Vital signs showed blood pressure 140/86 mmHg, heart rate 92 beats/min, respiratory rate 27 breaths/min, and SpO<sub>2</sub> 94%. Physical examination revealed a sternotomy incision, shallow breathing pattern, limited chest expansion, and mild respiratory muscle spasms. Lung auscultation identified ronchi (+), while heart auscultation revealed diastolic murmur (+). Functional assessment showed an ICU Mobility Scale of 1, a Borg Scale of 5/20, and chest expansion of approximately 2 cm. Supporting examinations showed dilation of the ascending aorta and preserved left ventricular function (LVEF 54.1%).

Table 1. Intervention protocol

Type of intervention	Dose	Purpose
Breathing exercise	F: 3 times/day I: mild, Borg ≤3, SpO <sub>2</sub> ≥95% T: 5-10 minute T: Deep Breathing & Diaphragmatic breathing	Improves lung ventilation and expansion
ROM exercise	F: 2-3 times/day I: 3 set 8 rep T: 5-10 minute T: aktif ROM	Maintains joint flexibility and muscle strength
Early mobilization	F: 1-2 times/day I: mild, Borg ≤3 T: 5-10 minute/session T: sitting → standing → walking	Improves sitting, standing, and walking abilities

Physical therapy interventions include breathing exercises, active range of motion (ROM) exercises, and progressive mobilization during Phase I of cardiac rehabilitation. Breathing exercises are performed three times a day for 5–10 minutes at low intensity to improve lung ventilation. Active ROM exercises are given two to three times a day (three sets of eight repetitions) to maintain joint flexibility and muscle strength. Progressive mobilization is performed once or twice a day for 5–10 minutes at a light intensity, starting from sitting, continuing to standing, and progressing to walking in place to improve functional capacity (Table 1).

Patient safety is monitored through symptoms, vital signs, and the Borg Pain Scale (RPE). Exercise is stopped if chest pain, dizziness, nausea, or severe shortness of breath occurs. Exercise is stopped if there is an abnormal response in vital signs: changes in systolic blood pressure (>20 mmHg increase or >10 mmHg decrease), heart rate (>30 bpm increase or >10 bpm decrease), respiratory rate >24 breaths/minute, or oxygen saturation (SpO<sub>2</sub>) <95%. Exercise intensity is maintained at RPE ≤3 and reduced if it exceeds the limit.

The main results were clinical improvement in respiratory function and functional status. Respiratory function was evaluated using respiratory rate, SpO<sub>2</sub>, chest expansion, and auscultation, while functional status included mobility (ICU Mobility Scale), exercise tolerance and fatigue (Borg RPE Scale), pain intensity (Wong-Baker Scale), and hemodynamic response (blood pressure, heart rate). Measurements were taken before and after three physiotherapy sessions to determine the effectiveness and safety of the intervention.

## RESULTS

### Participant follow-up and intervention adherence

Patients completed three consecutive Phase I cardiac rehabilitation sessions without interruption. Each session lasted approximately 30 minutes and consisted of structured breathing exercises and progressive early mobilization. Compliance with the intervention protocol was 100%, and no sessions were missed.

During the intervention period, no adverse events related to the exercises were observed. Vital signs were continuously monitored before, during, and after therapy. No signs of hemodynamic instability, orthostatic hypotension, arrhythmia, oxygen desaturation, or excessive fatigue were identified. The patient demonstrated good tolerance to the gradual progression from bed mobility to sitting and standing activities.

## Evaluation of functional and respiratory improvement

### Vital Sign

Based on daily evaluation records, peripheral oxygen saturation gradually increased from 94% to 100%, while respiratory rate decreased from 27 to 20 breaths per minute. These changes indicate improved ventilation efficiency and better oxygen diffusion. There were no episodes of desaturation (<90%) during mobilization, confirming adequate respiratory tolerance.

Blood pressure and heart rate remained within physiological limits throughout all sessions, indicating stable hemodynamic adaptation during low-intensity rehabilitation. The absence of orthostatic hypotension or arrhythmia indicates that early mobilization was safely implemented in the acute postoperative phase.

### Pain

Pain intensity measured using the Wong Baker assessment scale decreased from 4/10 to 0/10 over three sessions, reflecting reduced sternotomy discomfort and increased tolerance to movement.

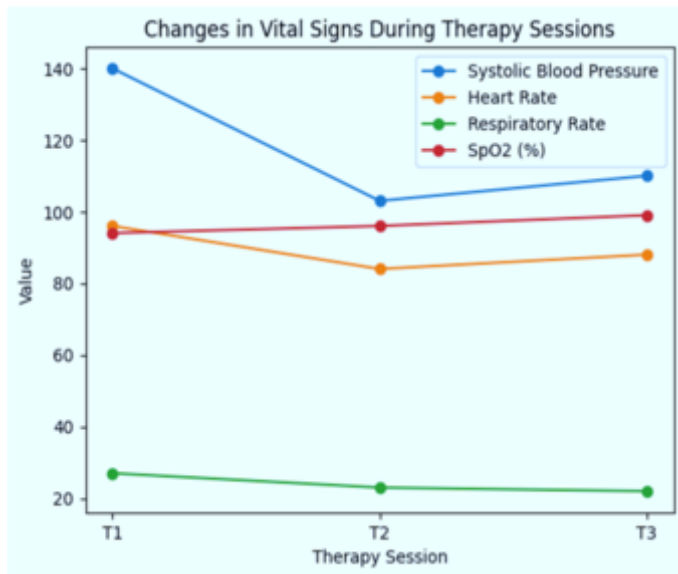


Figure 1. Vital sign

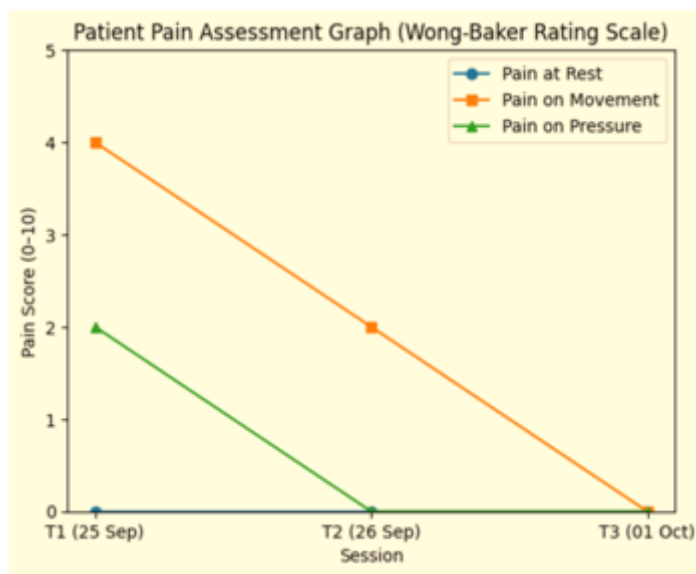


Figure 2. Pain with Wong Baker rating scale

### Thoracic expansion

Thoracic expansion was measured at three anatomical points: the armpit, ICS 4, and xiphoid process. A progressive increase was observed throughout the session. The greatest increase occurred at the armpit level (approximately 2.0 cm to 2.5 cm), followed by the xiphoid process level (1.0 cm to 1.5 cm), while a moderate increase was recorded at ICS 4 (1.0 cm to 1.2 cm). These findings indicate improved chest wall mobility and respiratory mechanics after structured breathing exercises during Phase I rehabilitation.

### Borg scale

Fatigue levels measured using the Borg Scale decreased from moderate fatigue to no reported fatigue, despite increased activity levels. These findings indicate improved exercise tolerance and adaptation.

### ICU mobility scale

Functional mobility improved significantly, as indicated by an increase in the ICU mobility scale (IMS) score from 1 (bed-bound activity only) to 6 (standing and light mobilization). This progress indicates a successful transition from bed-bound mobility to active functional movement without cardiovascular compromise.

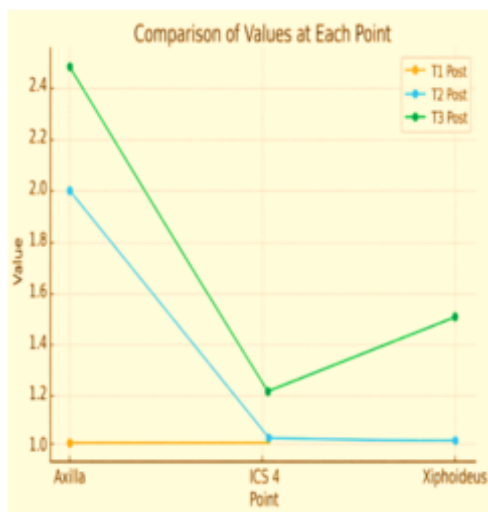


Figure 3. Thoracic expansion

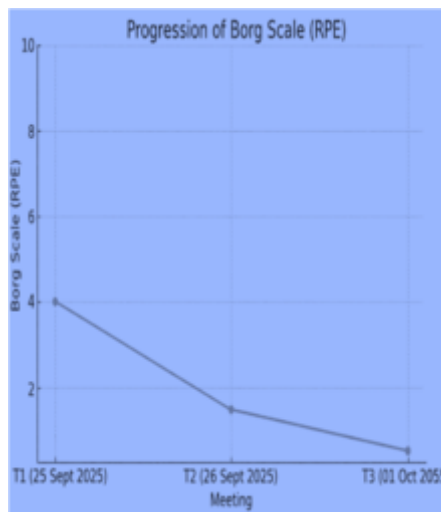


Figure 4. Borg Scale with RPE

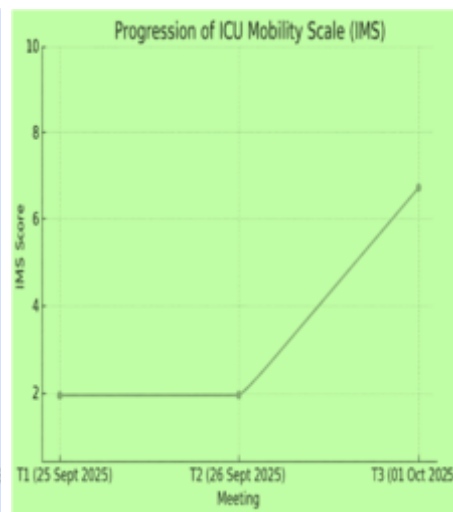


Figure 5. ICU mobility scale

Table 2. Evaluation of functional and respiratory improvement

Session	SpO <sub>2</sub>	Respiratory rate	Blood pressure	Heart rate	Wong Baker rating scale	ICU mobility scale	Borg scale with RPE
Session 1 [25 September 2025]	Pre: 94% Post: 97%	Pre: 27x/min Post: 29x/min	Pre: 140/86 mmHg Post: 133/95 mmHg	Pre: 96x/min Post: 101x/min	4/10	1	5
Session 2 [26 September 2025]	Pre: 96% Post: 98%	Pre: 23x/min Post: 22x/min	Pre: 103/81 mmHg Post: 103/81 mmHg	Pre: 84x/min Post: 87x/min	2/10	4	1
Session 3 [01 Oktober 2025]	Pre: 99% Post: 100%	Pre: 22x/min Post: 20x/min	Pre: 110/71 mmHg Post: 103/81 mmHg	Pre: 88x/min Post: 92x/min	0/10	6	0

This comparison shows clinically significant improvement in respiratory parameters, pain levels, and functional mobility after three sessions of structured rehabilitation. The decrease in respiratory rate accompanied by an increase in oxygen saturation reflects improvement in lung mechanics and ventilation efficiency. A five-point increase in the IMS score represents substantial functional progress in a short intervention period, indicating effective prevention of bed rest-related deconditioning. Additionally, a decrease in perceived exertion despite increased mobility indicates improved cardiopulmonary tolerance and early adaptation to physical stress. Overall, these findings suggest that structured breathing exercises combined with early mobilization in Phase I of cardiac rehabilitation contribute to measurable improvements in respiratory stability, pain reduction, and functional independence without compromising hemodynamic safety.

## DISCUSSION

The results of this study indicate that the combination of breathing exercises and early mobilization has a significant clinical impact on respiratory recovery and functional outcomes in patients after heart surgery. The increase in SpO<sub>2</sub> and decrease in RR reflect improvements in alveolar ventilation and oxygen diffusion efficiency. Physiologically, the post-sternotomy condition often causes decreased chest expansion and impaired breathing patterns due to pain and diaphragmatic inhibition. Therefore, diaphragmatic breathing activation is essential to restore normal ventilation patterns. These findings are in line with a study [7] stating that early respiratory physiotherapy can increase oxygen saturation and reduce the risk of postoperative atelectasis. Additionally, diaphragmatic exercises have been shown to reduce the use of accessory muscles, thereby decreasing respiratory effort and additional respiratory muscle spasms [8]. Increased chest expansion at the measurement point supports improved chest wall mechanics and lung elasticity [9,18-21].

From a functional perspective, an increase in the Intensive Care Unit Mobility Scale (IMS) score from 1 to 6 indicates significant progress in mobilization without hemodynamic instability. This proves that early mobilization is not only safe but also effective in preventing deconditioning due to bed rest. Research [11] reports that early mobilization contributes to increased muscle strength and reduced length of hospital stay compared to patients who are not mobilized. This effect is likely due to improved systemic circulation, stimulation of the cardiovascular system, and activation of peripheral muscles that accelerate physiological adaptation to activity.

The combination of breathing exercises and early mobilization shows synergistic effects. Optimizing oxygenation through breathing exercises supports increased activity tolerance during mobilization, while mobilization improves tissue perfusion and overall functional capacity. This approach is consistent with the principles of Enhanced Recovery After Surgery (ERAS), which emphasizes mobilization and breathing exercises as key strategies to accelerate recovery without increasing the risk of complications [15].

The safety of intervention in patients with high-risk conditions, including ascending aortic aneurysms, shows that phase I rehabilitation can be safely implemented when accompanied by close monitoring of vital signs and hemodynamic parameters [7,11,12]. The absence of complications such as orthostatic hypotension, arrhythmia, or respiratory distress reinforces that a stepwise, patient-tolerance-based approach effectively prevents excessive physiological responses.

Although the results show consistent clinical improvement marked by reduced pain, increased chest expansion, and stable respiratory parameters [8,14,15] interpretation of the findings must remain cautious because the single-case study design does not allow for broad generalization. The absence of a control group also limits the ability to separate the effects of the intervention from the natural postoperative healing process.

Therefore, this study reinforces the evidence that the combination of breathing exercises and early mobilization contributes significantly to the optimization of phase I cardiac rehabilitation. However, research with an experimental design and a larger sample size is needed to confirm the effectiveness and determine the magnitude of the intervention's effects more accurately.

## CONCLUSION

Structured phase I cardiac rehabilitation combining breathing exercises and progressive early mobilization during three sessions improves respiratory stability, chest expansion, pain control, and functional mobility in patients after aortic valve replacement with ascending aortic aneurysm. Oxygenation and respiratory efficiency improved while hemodynamic parameters remained stable, indicating safe physiological adaptation in the acute postoperative phase. Full compliance and carefully monitored low-intensity progression contributed to these outcomes. This case highlights the effectiveness and feasibility of combining respiratory therapy and early mobilization to accelerate recovery and prevent deconditioning in high-risk patients following cardiac surgery.

## Ethical consideration, competing interest and source of funding

- This study has been approved by the Health Research Ethics Committee [KEPK] of the Faculty of Health Sciences, Universitas Muhammadiyah Surakarta, with number 1608/KEPK-FIK/X/2025.
- There is no conflict of interest related to this publication.
- Source of funding is authors.

## REFERENCES

1. Putri AND, Komalasari DR, Gani P, Dewi DQ. Penatalaksanaan fisioterapi pada pasien dengan post-op coronary artery bypass graft (CABG): a case study. Acad Physiother Conf Proceeding. 2024;1(1):471-8.

2. Kemenkes RI. Peringatan hari jantung sedunia 2021: Jaga jantungmu untuk hidup lebih sehat. Jakarta: Kementerian Kesehatan Republik Indonesia; 2021.
3. Zhang MK, Li LN, Xue H, Tang XJ, Sun H, Wu QY. Left ventricle reverse remodeling in chronic aortic regurgitation patients with dilated ventricle after aortic valve replacement. *J Cardiothorac Surg.* 2022;17(1):1-7.
4. Marigliano AN, Ortiz JT, Casas J, Evangelista A. Aortic regurgitation: from valvular to myocardial dysfunction. *J Clin Med.* 2024;13(10).
5. Balint B, Federspiel JM, Schwab T, Ehrlich T, Ramsthaler F, Schäfers HJ. Aortic regurgitation is associated with ascending aortic remodeling in the nondilated aorta. *Arterioscler Thromb Vasc Biol.* 2021;41(3):1179-90.
6. Diartama AAA, Sari PI, Widiana IK. Optimalisasi pencitraan CT whole aorta pasca-AVR: teknik meminimalisir artefak pulsasi. *Bali Heal J.* 2024;8(2):75-96.
7. Afxonidis G, Moysidis DV, Papazoglou AS, Tsagkaris C, Loudovikou A, Tagarakis G, et al. Efficacy of early and enhanced respiratory physiotherapy and mobilization after on-pump cardiac surgery: a prospective randomized controlled trial. *Healthcare (Basel).* 2021;9(12):1-11.
8. Ariyanti AC, Perdana SS, Gani P, Indah DO. Breathing exercise dan mobilisasi bertahap terhadap kemampuan fungsional pada pasien pasca operasi double valve replacement: case report. *Acad Physiother Conf Proceeding.* 2024;167-75.
9. Basyasyah FS, Herawati I. Enhancing thoracic expansion in active smokers: the impact of deep breathing exercises – an experimental study. *Scientific Report.* 2025;13(01):59-64.
10. Rahman F, Wulandari W, Hastuti RP, Auliya F, Pasya MSN, Hidayat I, et al. Efektifitas pemberian breathing exercise terhadap penderita hipertensi di Posbindu Desa Siwal, Kecamatan Baki, Kabupaten Sukoharjo. *Natl Conf Health Sci (NCoHS).* 2022;114-20.
11. Kanejima Y, Shimogai T, Kitamura M, Ishihara K, Izawa KP. Effect of early mobilization on physical function in patients after cardiac surgery: a systematic review and meta-analysis. *Int J Environ Res Public Health.* 2020;17(19):1-11.
12. Radi B, Tiksnadi BB, Dwiputra B, Sarasvati D, Ambari AM. Panduan rehabilitasi kardiovaskular. Jakarta: Perhimpunan Dokter Spesialis Kardiovaskular Indonesia (PERKI); 2019.
13. Tanner TG, Colvin MO. Pulmonary complications of cardiac surgery. *Lung.* 2020;198(6):889-96.
14. Zhou N, Fortin G, Balice M, Kovalska O, Cristofini P, Ledru F, et al. Evolution of early postoperative cardiac rehabilitation in patients with acute type A aortic dissection. *J Clin Med.* 2022;11(8).
15. Malvindi PG, Bifulco O, Berretta P, Galeazzi M, Alfonsi J, Cefarelli M, et al. The enhanced recovery after surgery approach in heart valve surgery: a systematic review of clinical studies. *J Clin Med.* 2024;13(10).
16. Corovic M, Mosleh K, Puglisi O, Cameron M, Crawshaw J, Styra R, et al. JUMPSTART: evaluation of an early mobilization program following transcatheter aortic valve replacement. *BMC Cardiovasc Disord.* 2025;25(1):22-8.
17. Acob JR, Nugroho HS, Auta TT. Publication Opportunities of Non-research Articles in Health. *Health Notions.* 2021 Jan 21;5(01):38-40.
18. Selickman J, Marini JJ. Chest wall loading in the ICU: pushes, weights, and positions. *Annals of Intensive Care.* 2022 Jan 1;12(1):103-8.
19. Marini JJ, Gattinoni L. Improving lung compliance by external compression of the chest wall. *Critical Care.* 2021 Jul 28;25(1):264-8.
20. Dorado JH, Accoce M, Plotnikow G. Chest wall effect on the monitoring of respiratory mechanics in acute respiratory distress syndrome. *Revista Brasileira de Terapia Intensiva.* 2018;30:208-18.
21. Park SJ, Kim SH, Min KO. The immediate effects of rib cage joint mobilization and chest wall stretch on muscle tone and stiffness of respiratory muscles and chest expansion ability in patients with chronic stroke. *Journal of Physical Therapy Science.* 2017;29(11):1960-3.